

## PAPER

## Bilateral grey-matter increase in the putamen in primary blepharospasm

T Etgen, M Mühlau, C Gaser, D Sander



*J Neurol Neurosurg Psychiatry* 2006;**77**:1017–1020. doi: 10.1136/jnnp.2005.087148

See end of article for authors' affiliations

Correspondence to: T Etgen, Department of Neurology, Klinikum Traunstein, Cuno-Niggel-Strasse 3, D-83278 Traunstein, Germany; thorleif.etgen@klinikum-traunstein.de

Received 27 December 2005  
Revised version received 24 April 2006  
Accepted 29 April 2006  
Published Online First 11 May 2006

**Background:** Primary blepharospasm is a focal dystonia characterised by excessive involuntary closure of the eyelids. The pathophysiology of primary blepharospasm is unresolved.

**Aim:** To pinpoint grey-matter changes that are associated with primary blepharospasm.

**Methods:** 16 right-handed patients with primary blepharospasm (mean age 67.4 (SD 4.3) years; 12 women) were compared with 16 healthy volunteers matched for sex and age. High-resolution T1-weighted magnetic resonance imaging of each participant was obtained and analysed by voxel-based morphometry, a method to detect regionally specific differences in grey matter between patients and control group. To evaluate whether the identified grey-matter changes were correlated with the duration of primary blepharospasm or botulinum neurotoxin treatment (BoNT), separate regression analyses were carried out.

**Results:** In patients with primary blepharospasm, grey-matter increase in the putamina was observed, whereas regression analyses did not indicate a correlation between grey-matter increases and the duration of primary blepharospasm or BoNT. Grey-matter decrease was detected in the left inferior parietal lobule; here regression analyses of grey-matter decrease showed a significant ( $p=0.013$ ) correlation of grey-matter decrease with the duration of BoNT.

**Conclusions:** The data suggest structural changes in primary blepharospasm and point to a crucial role of the putamen for the pathophysiology of this focal dystonia.

Blepharospasm is a common neurological disorder with a prevalence between 12 and 133 per million.<sup>1</sup> This focal dystonia is characterised by excessive involuntary closure of the eyelids, typically caused by spasms of the orbicularis oculi muscles. Primary blepharospasm is a disorder in which dystonia is the only clinical sign, without any identifiable exogenous cause or other inherited or degenerative disease. Accordingly, no lesions can be detected on routine magnetic resonance imaging (MRI). By contrast, secondary blepharospasm is an identifiable disorder and associated lesions have been documented in the basal ganglia, diencephalon, brain stem and cerebellum.<sup>2–6</sup>

The pathophysiology of primary blepharospasm is unclear. Therefore, we aimed at pinpointing grey-matter changes that are associated with primary blepharospasm. We compared a group of patients with a control group, matched for sex and age, using voxel-based morphometry (VBM), a method that allows averaging high-resolution MRI on people and hence comparisons at the group level.

VBM has been cross validated with region-of-interest measurements<sup>7–9</sup> and several studies have shown that structural changes identified by VBM are directly related to functional changes in brain activity.<sup>10–11</sup> Moreover, VBM has proved to be a powerful method in detecting regional differences in cerebral structure in various disorders such as narcolepsy,<sup>12</sup> restless legs syndrome,<sup>13</sup> idiopathic cervical dystonia<sup>14</sup> and focal hand dystonia.<sup>15</sup>

## PARTICIPANTS AND METHODS

### Patients and controls

Diagnosis of primary blepharospasm was established by a detailed history and a neurological examination carried out by an expert neurologist of our outpatient clinic for movement disorders (Department of Neurology, Technische Universität München, München, Germany). The severity of primary blepharospasm was assessed with the

Blepharospasm Disability Scale and the Severity Rating Scale.<sup>16</sup> Secondary forms of blepharospasm were excluded by history, clinical examination, laboratory tests and neuroimaging. The 16 patients included were right-handed with primary blepharospasm. Table 1 summarises the demographic and clinical details.

All patients had no neurological abnormalities except for primary blepharospasm and were on regular botulinum neurotoxin treatment (BoNT). The 16 right-handed healthy controls were matched for age and sex. The study was carried out according to the *Declaration of Helsinki* and all participants had given prior written informed consent.

### Data acquisition

High-resolution structural data were acquired on a 1.5-T Siemens Magnetom Symphony scanner (Erlangen, Germany) (standard two-channel birdcage head coil; magnetisation-prepared rapid gradient echo sequence; sagittal slices 160; repetition time (TR) 11.1 ms; echo time (TE) 4.3 ms; flip angle 15°; matrix size 224×256 mm; voxel size 1×1×1 mm). A neuroradiologist, who was blinded to the study, detected neither abnormal nor unusual findings in all the screened images.

### Image processing

VBM comprises the following steps:

- Spatial normalisation of all images to a standardised anatomical space to allow for spatial averaging
- Segmentation of images into grey and white matter as well as cerebrospinal fluid

**Abbreviations:** BoNT, botulinum neurotoxin treatment; FDG, <sup>18</sup>F-deoxyglucose; fMRI, functional magnetic resonance imaging; VBM, voxel-based morphometry

**Table 1** Demographic data of patients with primary blepharospasm and controls

	Patients	Controls
Women:men	12:4	12:4
Age (years)	67.4 (4.3)	65.3 (4.9)
Duration of PB (years)	6.5 (4.9)	NA
Age at onset of PB (years)	61.5 (7.1)	NA
Time from last BoNT (days)	39.9 (30.2)	NA
BDS at onset of PB	9.5 (3.3)	NA
SRS at onset of PB	1.9 (1.0)	NA
Duration of BoNT (years)	3.0 (3.2)	NA

Values are given as mean (SD).

BDS, Blepharospasm Disability Scale (0–26); BoNT, botulinum neurotoxin treatment; NA, not applicable; PB, primary blepharospasm; SRS, Severity Rating Scale (0–4).

- Group comparison of local grey-matter values across the whole brain.<sup>17</sup>

We used standard statistical parametric mapping software (SPM2, Wellcome Department of Cognitive Neurology, London, UK) to preprocess and analyse our data.<sup>18–20</sup> Image preprocessing was carried out according to the optimised protocol described by Good *et al.*<sup>21</sup> The resulting grey-matter images were smoothed with a Gaussian kernel of 12 mm full-width at half-maximum.

Voxel-by-voxel analysis of covariance was used to detect grey-matter differences between the groups. In this analysis, we used the age of each participant as a covariate to control for age-related effects. To avoid edge effects around the border between grey and white matter, we excluded all voxels with a grey-matter value <0.1 (maximum value 1.0). We thresholded our results at a height threshold of  $p < 0.001$  uncorrected and, additionally, at an extent threshold of  $p < 0.05$ , uncorrected (cluster level).<sup>22</sup> To evaluate whether the identified grey-matter changes were correlated with the duration of primary blepharospasm or BoNT, we carried out separate regression analyses. For this purpose, we extracted the raw values of each significant cluster (using the volume-of-interest function of SPM2). These raw values were fed as separate regression analyses (SPSS V.12.0.1). Grey-matter increases were controlled for a positive correlation, whereas grey-matter decreases were controlled for a negative correlation.

## RESULTS

Grey-matter increase was identified in the right ( $Z = 4.5$ ) and left ( $Z = 4.2$ ) putamen (fig 1). In both clusters of grey-matter

increase, regression analyses for the duration of primary blepharospasm and BoNT showed values of  $p > 0.7$  and, hence, did not indicate a correlation of the grey-matter increases with the duration of primary blepharospasm or BoNT.

Grey-matter decrease (fig 2) was found in the left inferior parietal lobule ( $Z = 4.7$ ). Here regression analyses showed a trend towards a correlation of grey-matter decrease with the duration of primary blepharospasm ( $p = 0.12$ ) and a significant correlation of grey-matter decrease with the duration of BoNT ( $p = 0.013$ ; fig 3).

## DISCUSSION

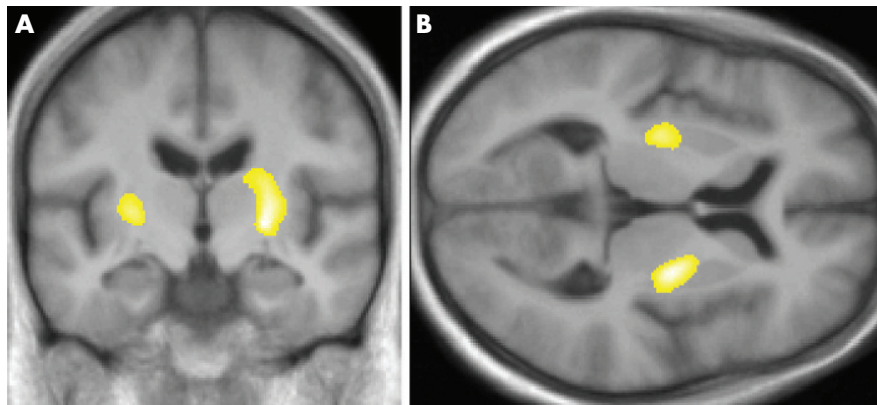
This study aimed at localising cerebral structures that play a crucial part in the pathophysiology of primary blepharospasm. By using VBM, we identified a bilateral grey-matter increase in the putamen and a grey-matter decrease in the left inferior parietal lobule.

Our finding of grey-matter increase in the putamen is consistent with other reports of striatal association with the pathophysiology of primary blepharospasm.

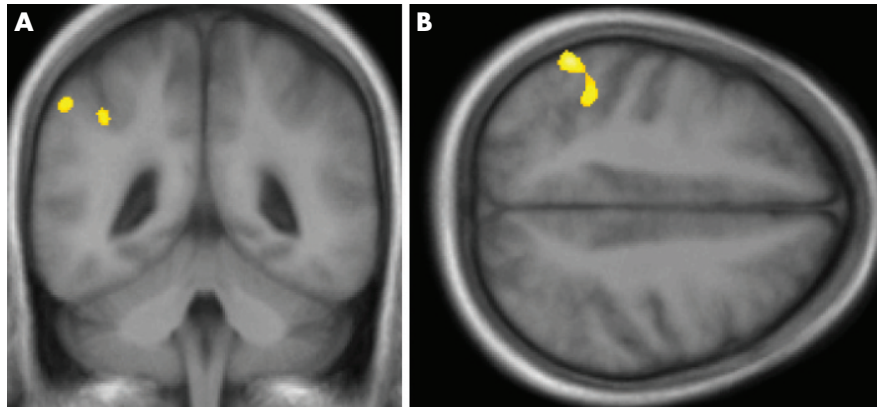
Animal models indicate an association of striatal structures with the pathogenesis of focal dystonias. In rhesus monkeys, unilateral lesions in the posterior putamen produce dystonia.<sup>23</sup> In a rat model, spasms of the lid-closing orbicularis oculi muscle similar to those found in primary blepharospasm are caused by the combination of a small depletion in striatal dopamine and slight weakening of the orbicularis oculi muscle.<sup>24</sup>

Studies on human lesions of secondary blepharospasm point to different regions including the basal ganglia, diencephalon, brain stem and cerebellum.<sup>2–6</sup> In idiopathic focal dystonia, conventional imaging showed changes in signal intensity in the putamen or globus pallidus, without gross radiological pathology.<sup>25–26</sup>

Some, but not all, neuroimaging studies suggest association of the putamen with the pathophysiology of primary blepharospasm. In a positron emission tomography (PET) study on patients with primary blepharospasm and hand dystonia, the *in vivo* binding of the dopaminergic radioligand (fluorine-18) spiperone was measured in the putamina and found to be decreased compared with that in unaffected controls.<sup>27</sup> <sup>18</sup>F-deoxyglucose (FDG)-PET and functional magnetic resonance imaging (fMRI) studies yielded conflicting results. In one FDG-PET study, patients with primary blepharospasm had hypermetabolism during wakefulness in the cerebellum and pons and hypometabolism during sleep in superior-medial frontal regions.<sup>28</sup> In contrast, another



**Figure 1** Grey-matter increase bilaterally in the putamen ( $Z = 4.5$  on the right; Montreal Neurological Institute (MNI) coordinates:  $x = 25$ ,  $y = -8$ ,  $z = 6$ ,  $z = 4.2$ ;  $Z$  value, 4.2 on the left; MNI coordinates:  $x = -26$ ,  $y = -13$ ,  $z = 4$ ). Results are projected on (A) coronal and (B) axial slices of the study-specific averaged T1-image in a standard stereotactic space derived from all the 32 study participants.



**Figure 2** Grey-matter decrease in the left inferior parietal lobule ( $Z=4.7$ ; MNI coordinates:  $x=-55$ ,  $y=-51$ ,  $z=49$ ). Results are projected on (A) coronal and (B) axial slices of the study-specific averaged T1-image.

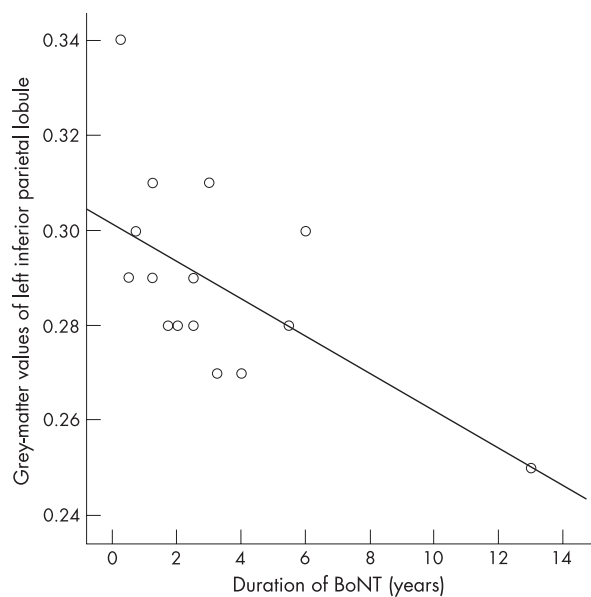
FDG-PET study showed striatal and thalamic hypermetabolism in patients with primary blepharospasm.<sup>29</sup> Using fMRI, one group reported a greater activation of the anterior visual cortex, anterior cingulate cortex, primary motor cortex, central region of the thalamus and superior cerebellum during spontaneous and voluntary blinking in patients with primary blepharospasm than in controls,<sup>30</sup> whereas another group compared spasms of the orbicularis oculi muscle in patients with primary blepharospasm with voluntary eye blinks of healthy controls and, notably, found spasms of the orbicularis oculi muscles in patients with primary blepharospasm accompanied by putaminal activation exactly at the site of grey-matter increase shown by our study.<sup>31</sup> In summary, several lines of evidence suggest a crucial role of the putamen in the pathophysiology of primary blepharospasm, which is confirmed by our structural data.

A functional putaminal change has been proposed that leads to a disturbance in the resistance of the blink system to environmental triggers and hence to lid spasms.<sup>32</sup> Such a functional putaminal change may go along with an increased number of neurones or synapses and, hence, grey-matter

increase as shown by our VBM study. The neuronal correlate of changes in grey matter detectable by VBM is, however, unknown. An alternative explanation has been proposed in a VBM study on another focal dystonia (idiopathic cervical dystonia).<sup>14</sup> Here, changes in grey matter were seen as a result of neuronal plasticity—that is, synaptic remodelling that follows excessive involuntary movements. The major difficulty interpreting not only VBM but also PET and fMRI studies on primary blepharospasm remains the question, whether the putaminal changes reflect the primary cause or the secondary consequences of primary blepharospasm including its treatment.

We, however, assume that the grey-matter increase shown by our study is more likely to reflect a primary putaminal alteration for the following reason: the patients included in our study varied with regard to the duration of primary blepharospasm and duration of BoNT (table 1). If these variables were considerably related to the grey-matter increase of the putamina, we would expect at least some correlation of this increase with the duration of primary blepharospasm or BoNT, but none of the respective regression analyses showed even a trend towards such a correlation. Longitudinal studies on patients with primary blepharospasm may help to finally resolve this question.

Moreover, we found grey-matter decrease in the left inferior parietal lobule in primary blepharospasm. Several case studies have reported unilateral dystonia contralateral to parietal lesions,<sup>33–35</sup> but we are not aware of unilateral parietal lesions resulting in a symmetric dystonia such as blepharospasm. The finding of grey-matter decrease in the parietal region only on the left side indicates the involvement of functions that are primarily related to the left parietal cortex. Accordingly, cortical sensory processing, which may be presented in the parietal cortex in a leftward-biased manner, has been postulated to be abnormal in dystonia.<sup>36–37</sup> Several further functions have, however, been related to the parietal cortex in a leftward-biased manner (eg, motor attention and movement selection,<sup>38</sup> integration of time and space,<sup>39</sup> and imitation<sup>40</sup>). Therefore, it is also conceivable that frequent spasms of the eye-closing orbicularis oculi muscles as present in primary blepharospasm lead to neuroplastic changes detectable by VBM.<sup>10–11</sup> In fact, our data point in this direction, as regression analyses showed a trend towards correlation of the grey-matter decrease with the duration of primary blepharospasm and a significant correlation with the duration of the BoNT. Therefore, we conclude that the grey-matter decrease in the left inferior parietal lobule is more likely to reflect a secondary cause rather than the primary cause of primary blepharospasm.



**Figure 3** Regression analysis of the correlation between grey-matter values of the left inferior parietal lobule and the duration of botulinum neurotoxin treatment (BoNT).

Our data suggest in vivo morphological changes in the putamen in primary blepharospasm and, hence, support the hypothesis of a pivotal role for the putamen in the pathophysiology of this focal dystonia.

## ACKNOWLEDGEMENTS

TE and his colleagues from the Department of Neurology (Technische Universität München) were supported by KKF-Fond 766160. We thank JP Rauschecker for reading an earlier version of this manuscript.

## Authors' affiliations

**T Etgen, M Mühlau, D Sander**, Department of Neurology, Technische Universität München, München, Germany

**C Gaser**, Department of Psychiatry, University of Jena, Jena, Germany

Competing interests: None declared.

## REFERENCES

- Hallett M. Blepharospasm: recent advances. *Neurology* 2002;**59**:1306–12.
- Grandas F, Lopez-Manzanera L, Traba A. Transient blepharospasm secondary to unilateral striatal infarction. *Mov Disord* 2004;**19**:1100–2.
- Jankovic J, Patel SC. Blepharospasm associated with brainstem lesions. *Neurology* 1983;**33**:1237–40.
- Larumbe R, Vaamonde J, Artieda J, et al. Reflex blepharospasm associated with bilateral basal ganglia lesion. *Mov Disord* 1993;**8**:198–200.
- Lee MS, Marsden CD. Movement disorders following lesions of the thalamus or subthalamic region. *Mov Disord* 1994;**9**:493–507.
- Verghese J, Milling C, Rosenbaum DM. Ptosis, blepharospasm, and apraxia of eyelid opening secondary to putaminal hemorrhage. *Neurology* 1999;**53**:652.
- Mummery CJ, Patterson K, Price CJ, et al. A voxel-based morphometry study of semantic dementia: relationship between temporal lobe atrophy and semantic memory. *Ann Neurol* 2000;**47**:36–45.
- Vargha-Khadem F, Watkins K, Price C, et al. Neural basis of an inherited speech and language disorder. *Proc Natl Acad Sci USA* 1998;**95**:12695–700.
- Woermann F, Free S, Koepp M, et al. Voxel-by-voxel comparison of automatically segmented cerebral gray matter—a rater-independent comparison of structural MRI in patients with epilepsy. *Neuroimage* 1999;**10**:373–84.
- Gaser C, Schlaug G. Brain structures differ between musicians and non-musicians. *J Neurosci* 2003;**23**:9240–5.
- Draganski B, Gaser C, Busch V, et al. Neuroplasticity: changes in grey matter induced by training. *Nature* 2004;**427**:311–2.
- Draganski B, Geisler P, Hajak G, et al. Hypothalamic gray matter changes in narcoleptic patients. *Nat Med* 2002;**8**:1186–8.
- Etgen T, Draganski B, Ilg C, et al. Bilateral thalamic gray matter changes in patients with restless legs syndrome. *Neuroimage* 2005;**24**:1242–7.
- Draganski B, Thun-Hohenstein C, Bogdahn U, et al. "Motor circuit" gray matter changes in idiopathic cervical dystonia. *Neurology* 2003;**61**:1228–31.
- Garraux G, Bauer A, Hanakawa T, et al. Changes in brain anatomy in focal hand dystonia. *Ann Neurol* 2004;**55**:736–9.
- Fahn S. The assessment of the primary dystonias. In: Munsat T, ed. *The quantification of neurologic deficit*. Boston: Butterworths, 1989:242–5.
- Ashburner J, Friston KJ. Voxel-based morphometry—the methods. *Neuroimage* 2000;**11**:805–21.
- Ashburner J, Friston K. Multimodal image coregistration and partitioning—a unified framework. *Neuroimage* 1997;**6**:209–17.
- Friston KJ, Holmes A, Poline JB, et al. Statistic parametric maps in functional imaging: a general linear approach. *Hum Brain Mapp* 1995;**2**:189–210.
- Wright IC, McGuire PK, Poline JB, et al. A voxel-based method for the statistical analysis of gray and white matter density applied to schizophrenia. *Neuroimage* 1995;**2**:244–52.
- Good CD, Johnsrude IS, Ashburner J, et al. A voxel-based morphometric study of ageing in 465 normal adult human brains. *Neuroimage* 2001;**14**:21–36.
- Friston KJ, Holmes A, Poline JB, et al. Detecting activations in PET and fMRI: levels of inference and power. *Neuroimage* 1996;**4**:223–35.
- Burns LH, Pakzaban P, Deacon TW, et al. Selective putaminal excitotoxic lesions in non-human primates model the movement disorder of Huntington disease. *Neuroscience* 1995;**64**:1007–17.
- Schiccatano EJ, Basso MA, Evinger C. Animal model explains the origins of the cranial dystonia benign essential blepharospasm. *J Neurophysiol* 1997;**77**:2842–6.
- Iwata M. MRI pathology of basal ganglia in dystonic disorders. *Adv Neurol* 1993;**60**:535–9.
- Schneider S, Feifel E, Ott D, et al. Prolonged MRI T2 times of the lentiform nucleus in idiopathic spasmodic torticollis. *Neurology* 1994;**44**:846–50.
- Perlmutter JS, Stambuk MK, Markham J, et al. Decreased [18F] spiperone binding in putamen in idiopathic focal dystonia. *J Neurosci* 1997;**17**:843–50.
- Hutchinson M, Nakamura T, Moeller JR, et al. The metabolic topography of essential blepharospasm: a focal dystonia with general implications. *Neurology* 2000;**55**:673–7.
- Esmaeli-Gutstein B, Nahmias C, Thompson M, et al. Positron emission tomography in patients with benign essential blepharospasm. *Ophthalmol Plast Reconstr Surg* 1999;**15**:23–7.
- Baker RS, Andersen AH, Morecraft RJ, et al. A functional magnetic resonance imaging study in patients with benign essential blepharospasm. *J Neuroophthalmol* 2003;**23**:11–5.
- Schmidt KE, Linden DE, Goebel R, et al. Striatal activation during blepharospasm revealed by fMRI. *Neurology* 2003;**60**:1738–43.
- Evinger C, Perlmutter JS. Blind men and blinking elephants. *Neurology* 2003;**60**:1732–3.
- Nobbe FA, Krauss JK. Subdural hematoma as a cause of contralateral dystonia. *Clin Neurol Neurosurg* 1997;**99**:37–9.
- Burguera JA, Bataller L, Valero C. Action hand dystonia after cortical parietal infarction. *Mov Disord* 2001;**16**:1183–5.
- Khan AA, Sussman JD. Focal dystonia after removal of a parietal meningioma. *Mov Disord* 2004;**19**:714–6.
- Tinazzi M, Frasson E, Polo A, et al. Evidence for an abnormal cortical sensory processing in dystonia: selective enhancement of lower limb P37–N50 somatosensory evoked potential. *Mov Disord* 1999;**14**:473–80.
- Tinazzi M, Priori A, Bertolasi L, et al. Abnormal central integration of a dual somatosensory input in dystonia. Evidence for sensory overflow. *Brain* 2000;**123**:42–50.
- Rushworth MF, Johansen-Berg H, Gobel SM, et al. The left parietal and premotor cortices: motor attention and selection. *Neuroimage* 2003;**20**(Suppl 1):S89–100.
- Assmus A, Marshall JC, Ritzl A, et al. Left inferior parietal cortex integrates time and space during collision judgments. *Neuroimage* 2003;**20**(Suppl 1):S82–8.
- Mühlau M, Hermsdörfer J, Goldenberg G, et al. Left inferior parietal dominance in gesture imitation: an fMRI study. *Neuropsychologia* 2005;**43**:1086–98.