

Research report

Hippocampal volume in chronic posttraumatic stress disorder (PTSD): MRI study using two different evaluation methods

A. Jatzko ^{a,1}, S. Rothenhöfer ^{a,1}, A. Schmitt ^a, C. Gaser ^c, T. Demirakca ^a,
W. Weber-Fahr ^b, M. Wessa ^d, V. Magnotta ^e, D.F. Braus ^{b,*}

^a Central Institute of Mental Health, Faculty for Clinical Medicine Mannheim, University of Heidelberg, Germany

^b NeuroImage Nord, Department of Psychiatry, University Medical Center Hamburg-Eppendorf, University of Hamburg, Martinistraße 52, D-20246 Hamburg, Germany

^c Department of Psychiatry, University of Jena, Germany

^d Central Institute of Mental Health, Department of Clinical and Cognitive Neuroscience, University of Heidelberg, Germany

^e The Department of Radiology, The University of Iowa Hospital and Clinics, USA

Received 25 October 2005; received in revised form 8 March 2006; accepted 10 March 2006

Available online 15 May 2006

Abstract

The hippocampus is discussed as one of the key regions in the pathogenesis of Posttraumatic Stress Disorder (PTSD). MRI results concerning the volume of the hippocampus are, however, inconsistent. This may be due to the heterogeneity of patients' traumata or postprocessing of the imaging data. To overcome these problems, the present study investigates volume changes in well-characterized chronic PTSD patients in comparison to controls using two different evaluation methods.

Material and Methods: 15 patients with chronic PTSD, traumatized at the same air show plane crash in 1988 (Ramstein, Germany), and 15 matched healthy controls participated in this study. All patients suffered from significant impairment by the PTSD; none had a history of drug or alcohol abuse. Hippocampus volume changes were processed by a semi-automated standard procedure performed with BRAINS2 as well as the voxel based morphometry (VBM) using SPM2.

Results: No differences in total brain grey or white matter were detected between patients and controls. No differences in total hippocampal volume or in right and left parts were seen, even when hippocampal volumes were corrected by total brain volume or correlated with clinical data. Finally, no significant differences were detected between patients and controls in hippocampal regions using VBM.

Discussion: This is the first study examining long-term changes in hippocampal volumes in chronic PTSD patients compared to matched controls using two different evaluation methods. Neither conventional volumetry nor VBM could detect any differences in the volume and structure. This supports the hypothesis that previously described hippocampal volume reduction is not necessarily due to PTSD or at least that, after 15 years, volume changes have been restored or have not yet developed.

© 2006 Elsevier B.V. All rights reserved.

Keywords: PTSD; Posttraumatic stress disorder; Hippocampus; MRI; Volumetry; Voxel based morphometry; VBM

* Corresponding author. Tel.: +49 40 42803 7549; fax: +49 40 42803 7666.

E-mail address: dbraus@uke.uni-hamburg.de (D.F. Braus).

¹ Equal contribution to this work.

1. Introduction

One of the key players in the pathophysiology of post-traumatic stress disorder (PTSD) is the hippocampus-

formation, which is involved in memory processing and therefore thought to be functionally important for the pathogenesis of the persistent reexperiencing symptoms in the context of trauma. Early structural findings in traumatized patients illustrated a reduction in hippocampal volume of 5–12% (Bremner et al., 1997; Stein et al., 1997). This led to the theory that during acute trauma and its aftermath, the hippocampus might be damaged by the release of neurotoxic agents such as high levels of cortisol (Sapolsky, 1996), whereas cortisol levels have been found lower in PTSD (Yehuda et al., 1995). However, these results could not be consistently replicated: while 11 cross-sectional studies (Bremner et al., 1995, 1997, 2003; Gurvits et al., 1996; Hedges et al., 2003; Lindauer et al., 2004; Schuff et al., 1997; Shin et al., 2004; Stein et al., 1997; Villarreal et al., 2002; Vythilingam et al., 2002) described smaller hippocampus volumes in PTSD compared to non-PTSD patients or controls, 9 studies (Bonne et al., 2001; Carrion et al., 2001; De Bellis et al., 2001, 1999, 2002; Fennema-Notestine et al., 2002; Neylan et al., 2004; Pederson et al., 2004; Winter and Irle, 2004) failed to show such a relationship. More importantly, the only two longitudinal studies in the literature (Bonne et al., 2001; De Bellis et al., 2001) did not identify structural alterations, which argues against the model of severe neurotoxicity in the hippocampus. Furthermore, Gilbertson et al. (2002) found evidence in monozygotic twins discordant for trauma exposure which suggest that smaller hippocampi may rather constitute a predisposing risk factor for the development of stress related psychopathology. Studies of dizygotic twins would be needed to clarify whether genetic or environmental risk factors are the basis of the results shown above.

In addition to biological reasons, the substantial differences found for volume changes in the literature across studies also point to methodological limitations. Bremner et al. (1995, 1997, 2003) for example traced only the middle portion, while other studies measured the entire hippocampus. Furthermore, there is a wide range of hippocampal sizes (2.1 up to 6.4 cm³) reported (Stein et al., 1997), revealing that manual techniques are highly rater dependent which limits the interpretation in psychiatric patients. Automatic procedures, however, are more dependent on the quality of MRI images and the capability to distinguish between grey and white matter compared to manual techniques.

The basic idea of the present study was to employ the two techniques upon the same subjects to compare and validate the findings in the hippocampus volume and structure in a well-defined sample of chronic PTSD patients.

2. Material and methods

2.1. Subjects

Our study sample consisted of 30 subjects: 15 patients (13 male, 2 female) suffering from chronic PTSD according to DSM IV after witnessing an air show crash (Ramstein, Germany, 1988) of an airplane crashing into the spectator crowd. None of the subjects had been taking psychoactive drugs on a regular basis three months prior to the study. Eight patients had taken antidepressive medications (serotonin reuptake inhibitors) for a short time in the past but not on a regular basis, seven had not. A comparison group of 15 matched healthy controls was also recruited consisting of 13 male and 2 female healthy age and handedness matched subjects without any history of mental or significant physical disorders (patients: 48.2 years \pm 12.2, controls: 47.9 years \pm 12.9). Symptom severity was measured using the German version of the clinician-administered PTSD scale [CAPS] (Schnyder and Moergeli, 2002), German version of the Posttraumatic Stress Diagnostic Scale [PDS] (Foa et al., 1993) and German version of the 22 item Impact of Event Scale Revised [IES-R] (Horowitz et al., 1979). To characterize possible comorbidity with a depressive disorder, the German version of the Beck Depression Inventory [BDI] (Hautzinger, 1991) was performed.

All subjects received a comprehensive description of the MRI study and gave their written informed consent. Exclusion criteria for both groups included lifetime history of major medical or psychiatric diagnoses such as schizophrenia, bipolar, psychotic disorders, alcohol or other substance dependence or abuse, neurological disorders, acute organic disorders and standard MRI exclusion criteria. Depressive and anxiety disorders were no exclusion criteria because of the common comorbidity in PTSD patients.

2.2. MRI acquisition and postprocessing

The MRI study was performed with a Siemens Vision 1.5 Tesla MR-scanner. Due to the constraints of the postprocessing software, two different high resolution 3D T1 weighted sequences were acquired (3D MP-RAGE: echo time [TE]=4.4 ms, repetition time [TR]=11.4 ms, inversion time [TI]=300 ms, flip angle= 12°, field of view [FOV]=256×256×162 mm, no gap, voxel size was 1×1×1 mm and a 3D FLASH sequence: TE= 5 ms, TR=15 ms, flip angle=30°, FOV=256×256×162 mm, no gap, voxel size was 1×1×1 mm). In 26 participants, both MRI data sets were measured,

in the remaining 4 only the MP-RAGE was available for analysis. The MRI data were assigned identification numbers so that the investigator performing the segmentations and parcellations could remain blind to any correspondence between images and subjects.

2.3. Image analysis

All anatomical tracings in BRAINS2 (Andreasen et al., 1992; Magnotta et al., 2002) (Fig. 1) were performed by a single rater (SR), who was blind to the subjects' diagnostic status, gender and age. Volumes were processed by a semi-automated standard procedure. The anatomical landmarks and boundaries used for the volumetric method were based on the morphological description given by Duvernoy (1998) and tracing guidelines by Pantel et al. (2000). Guide traces were defined on every fifth slice in the sagittal view. These traces are then projected to the coronal view where tracing was performed on every slice throughout the entire hippocampus. After 15 anatomical tracings, the procedure was repeated in random order with the same 15 subjects, to validate the accuracy of measurements. After the 8th repeated tracing the deviation on the following 7 repeated tracings was constantly smaller than 2%.

The second method was the rater independent voxel wise comparison of local grey matter concentrations with the voxel based morphometry (VBM) procedure described by Gaser and Schlaug (2003) and Good et al. (2001) in SPM2 (Wellcome Department of Imaging

Neuroscience, London, UK) using the MP-RAGE images. The T1 MP-RAGE images of all subjects were normalised and segmented by SPM2. From these images a specific grey matter template was produced and smoothed with 8 mm full-width half-maximum (FWHM) for further processing. Then every T1 image was segmented and resulting grey matter images were normalised (nonlinear, cutoff 25 mm) to the specific grey matter template. Estimated normalisation parameters were applied to the original T1 images and final segmentation was applied. The resulting grey matter images were finally smoothed with 10 mm FWHM and used for statistical evaluation.

2.4. Statistical methods

A two-sample *T*-Test was used to compare the hippocampal volumes measured by BRAINS2. The same calculation was performed with data corrected for age and total brain volume. In the PTSD group a regression between hippocampal size and CAPS, IES-R, PDS and BDI was performed.

For VBM the final grey matter probability maps were tested voxel wise using a two-sample *T*-test in SPM2 to measure group wise alterations in local grey matter density.

3. Results

All patients were significantly impaired by PTSD symptoms: CAPS (59+/-23), IES-R (70+/-19), PDS

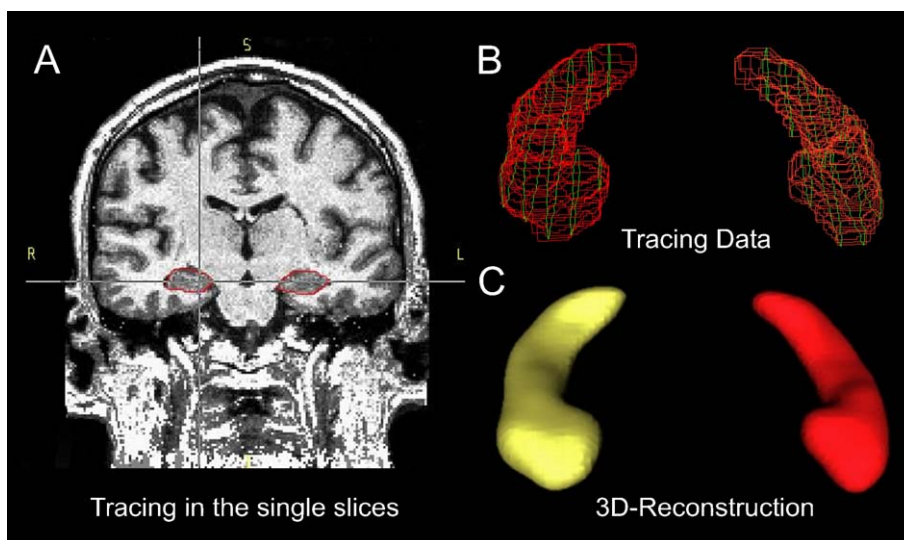


Fig. 1. Anatomical tracing with BRAINS2 (A) MRI-data, Tracings in red of both hippocampi on an MRI image in coronal plane. (B) Borders of both hippocampi in sagittal and coronal direction. We first traced the hippocampus on every 5th slice in sagittal view for guidance, before tracing every coronal slice from the entire hippocampus. (C) 3D-reconstruction of the Hippocampus. (For interpretation of the references to colour in this figure legend, the reader is referred to the web version of this article.)

(24+/- 14), BDI (22.8+/- 17.8). Two patients had suffered burns from the crash incident, one of 60% and one of 20% of their body surface.

3.1. Manual tracing with BRAINS2

There were no differences in raw values of total hippocampal volume, or the right or left hippocampus between patients and controls (Table 1). Furthermore, no differences were seen when hippocampal volumes were corrected by total brain volume or age. We observed no significant correlation between raw and corrected values of hippocampal volume and CAPS ($p=0.08$), IES-R ($p=0.42$), PDS ($p=0.41$), BDI ($p=0.26$) and their subscores.

3.2. VBM with SPM2

No significant differences were seen in total brain volume, grey and white matter (Table 1). No different atrophy scores such as ventricle brain ratios (VBR) were found for PTSD subjects (Table 1). There was a significant correlation between age and VBR ($p=0.042$) in the entire group, replicating studies of age dependent brain volume decline (Jernigan et al., 2001). With VBM, no differences between patients and controls were seen in the hippocampus or adjacent regions on either side (up to $p<0.05$ uncorrected).

4. Discussion

To the best of our knowledge, this is the first study examining changes in hippocampal volumes in well characterized chronic PTSD subjects, all traumatized at the same event, compared to matched controls using two different evaluation methods. Both evaluation techniques showed the same results. Neither method detected

any volume or structural differences in this region. Furthermore, no significant correlations between hippocampal volumes and clinical data have been found. Our results are in line with 6 cross-sectional studies, one twin and two longitudinal studies, supporting the hypothesis that a reduction of hippocampus volume is not necessarily linked to the development of PTSD (Winter and Irle, 2004).

Using semi-automated MRI postprocessing procedures, 11 studies have illustrated a volume reduction of the hippocampus. However, the majority of these studies did not describe the severity of PTSD evaluated by standardized scales. Therefore, the comparability of these studies is limited. Two studies characterizing the severity described volume alterations in less severe patients (Stein et al., 1997; Vythilingam et al., 2002) and two studies in patients with more severe symptoms (Gurvits et al., 1996; Villarreal et al., 2002). Two studies with less affected (Bonne et al., 2001; Fennema-Notestine et al., 2002) and one study with more affected patients (Gilbertson et al., 2002) showed no direct effects of PTSD on hippocampal volume. Another crucial limitation is the substantial differences in mean volume of the hippocampus reported across studies. These differences point to greater methodological limitations of manual tracing techniques, underscoring the need for standardized tracing methods. Furthermore, in contrast to our study, comorbidity such as substance abuse and drug or alcohol addiction has often not been excluded, but has been shown to reduce hippocampal volume (Agartz et al., 1999). Consequently studies should control for these substances.

Other common comorbidities like depressive disorders have been shown to have an effect on hippocampal volume. In our study the score for depressive symptoms was moderately high, which should, however, not be of relevance to our results, since findings in major depression point rather to a hippocampal volume reduction. However, the influence of medication, which has been reported to have positive effects on hippocampal volume reduction (Bremner and Vermetten, 2004), cannot be excluded in our study, since the patients were investigated cross-sectionally 15 years after trauma and serotonin reuptake inhibitors were taken by 8 out of 15 in the PTSD group for short times in the past. Other limitations of our study are the small group size of 15 subjects in each group and no additional group of trauma exposed subjects without PTSD.

The major strength of our study, however, is that all patients had been traumatized at the same incident on the same day, therefore having the same time frame for brain adaptation. Most previous studies have investigated groups of PTSD patients with different traumata and

Table 1
Measured brain volumes and ratios

	PTSD	SD	Controls	SD	T-value	p
Total brain volume	1474	161	1487	124	0.29	0.80
Hippocampal volume						
Total volume	7.3	0.9	7.1	0.7	-0.94	0.35
Right volume	3.7	0.5	3.6	0.4	-0.64	0.52
Left volume	3.7	0.4	3.5	0.4	-1.17	0.25
Gray matter	728	86	719	59	-0.30	0.8
White matter	468	50	469	48	0.05	0.96
CSF	278	40	299	40	1.40	0.17
Ventricle brain ratio	23.3	2.7	25.2	3.0	1.72	0.09

Volumes reported in cm³. Total brain volume, gray, white matter and CSF are measured in SPM, all hippocampus volumes are measured in BRAINS2.

adaptation times. So far all published studies looking at a post trauma period of less than 10 years have shown no hippocampal volume alteration (Bonne et al., 2001; Carrion et al., 2001; De Bellis et al., 2001, 1999, 2002). Studies describing a volume reduction were based on post trauma periods of longer than 18 years. Thus, our study fits in the time gap between 10 and 18 years post trauma, showing no volume decrease. Furthermore, in contrast to previous data, the present study does not rely on one postprocessing method of MRI images alone. In addition to the common manual evaluation of volume changes, VBM has the additional potential to look rater independently at significant structural differences in hippocampal grey matter, but also in adjacent regions, strengthening or attenuating findings from manual tracing. This helped to validate our rater dependent results, with both methods showing no group differences.

Before our preliminary results can be generalized, prospective MRI studies should be carried out in a larger sample with repeated measures over longer time periods under controlled conditions for substance abuse, medication status and psychiatric comorbidities.

References

- Agartz, I., Momenan, R., Rawlings, R.R., Kerich, M.J., Hommer, D.W., 1999. Hippocampal volume in patients with alcohol dependence. *Arch. Gen. Psychiatry* 56, 356–363.
- Andreasen, N.C., Cohen, G., Harris, G., Cizadlo, T., Parkkinen, J., Rezai, K., Swayze II, V.W., 1992. Image processing for the study of brain structure and function: problems and programs. *J. Neuro-psychiatry Clin. Neurosci.* 4, 125–133.
- Bonne, O., Brandes, D., Gilboa, A., Gomori, J.M., Shenton, M.E., Pitman, R.K., Shalev, A.Y., 2001. Longitudinal MRI study of hippocampal volume in trauma survivors with PTSD. *Am. J. Psychiatry* 158, 1248–1251.
- Bremner, J.D., Vermetten, E., 2004. Neuroanatomical changes associated with pharmacotherapy in posttraumatic stress disorder. *Ann. N. Y. Acad. Sci.* 1032, 154–157.
- Bremner, J.D., Randall, P., Scott, T.M., Bronen, R.A., Seibyl, J.P., Southwick, S.M., Delaney, R.C., McCarthy, G., Charney, D.S., Innis, R.B., 1995. MRI-based measurement of hippocampal volume in patients with combat-related posttraumatic stress disorder. *Am. J. Psychiatry* 152, 973–981.
- Bremner, J.D., Randall, P., Vermetten, E., Staib, L., Bronen, R.A., Mazure, C., Capelli, S., McCarthy, G., Innis, R.B., Charney, D.S., 1997. Magnetic resonance imaging-based measurement of hippocampal volume in posttraumatic stress disorder related to childhood physical and sexual abuse—a preliminary report. *Biol. Psychiatry* 41, 23–32.
- Bremner, J.D., Vythilingam, M., Vermetten, E., Southwick, S.M., McGlashan, T., Nazeer, A., Khan, S., Vaccarino, L.V., Soufer, R., Garg, P.K., Ng, C.K., Staib, L.H., Duncan, J.S., Charney, D.S., 2003. MRI and PET study of deficits in hippocampal structure and function in women with childhood sexual abuse and posttraumatic stress disorder. *Am. J. Psychiatry* 160, 924–932.
- Carrion, V.G., Weems, C.F., Eliez, S., Patwardhan, A., Brown, W., Ray, R.D., Reiss, A.L., 2001. Attenuation of frontal asymmetry in pediatric posttraumatic stress disorder. *Biol. Psychiatry* 50, 943–951.
- De Bellis, M.D., Keshavan, M.S., Clark, D.B., Casey, B.J., Giedd, J.N., Boring, A.M., Frustaci, K., Ryan, N.D., 1999. A.E. Bennett Research Award. Developmental traumatology. Part II: Brain development. *Biol. Psychiatry* 45, 1271–1284.
- De Bellis, M.D., Hall, J., Boring, A.M., Frustaci, K., Moritz, G., 2001. A pilot longitudinal study of hippocampal volumes in pediatric maltreatment-related posttraumatic stress disorder. *Biol. Psychiatry* 50, 305–309.
- De Bellis, M.D., Keshavan, M.S., Shifflett, H., Iyengar, S., Beers, S.R., Hall, J., Moritz, G., 2002. Brain structures in pediatric maltreatment-related posttraumatic stress disorder: a sociodemographically matched study. *Biol. Psychiatry* 52, 1066–1078.
- Duvernoy, H., 1998. *The Human Hippocampus: An Atlas of Applied Anatomy*. Springer, Berlin.
- Fennema-Notestine, C., Stein, M.B., Kennedy, C.M., Archibald, S.L., Jernigan, T.L., 2002. Brain morphometry in female victims of intimate partner violence with and without posttraumatic stress disorder. *Biol. Psychiatry* 52, 1089–1101.
- Foa, E.B., Riggs, D.S., Dancu, C.V., Rothbaum, B.O., 1993. Reliability and validity of a brief instrument for assessing post-traumatic stress disorder. *J. Traum. Stress* 6, 459–473.
- Gaser, C., Schlaug, G., 2003. Gray matter differences between musicians and nonmusicians. *Ann. N. Y. Acad. Sci.* 999, 514–517.
- Gilbertson, M.W., Shenton, M.E., Ciszewski, A., Kasai, K., Lasko, N.B., Orr, S.P., Pitman, R.K., 2002. Smaller hippocampal volume predicts pathologic vulnerability to psychological trauma. *Nat. Neurosci.* 5, 1242–1247.
- Good, C.D., Johnsruide, I.S., Ashburner, J., Henson, R.N., Friston, K.J., Frackowiak, R.S., 2001. A voxel-based morphometric study of ageing in 465 normal adult human brains. *Neuroimage* 14, 21–36.
- Gurvtis, T.V., Shenton, M.E., Hokama, H., Ohta, H., Lasko, N.B., Gilbertson, M.W., Orr, S.P., Kikinis, R., Jolesz, F.A., McCarley, R.W., Pitman, R.K., 1996. Magnetic resonance imaging study of hippocampal volume in chronic, combat-related posttraumatic stress disorder. *Biol. Psychiatry* 40, 1091–1099.
- Hautzinger, M., 1991. The Beck Depression Inventory in clinical practice. *Nervenarzt* 62, 689–696.
- Hedges, D.W., Allen, S., Tate, D.F., Thatcher, G.W., Miller, M.J., Rice, S.A., Cleavinger, H.B., Sood, S., Bigler, E.D., 2003. Reduced hippocampal volume in alcohol and substance naive Vietnam combat veterans with posttraumatic stress disorder. *Cogn. Behav. Neurol.* 16, 219–224.
- Horowitz, M., Wilner, N., Alvarez, W., 1979. Impact of Event Scale: a measure of subjective stress. *Psychosom. Med.* 41, 209–218.
- Jernigan, T.L., Archibald, S.L., Fennema-Notestine, C., Gamst, A.C., Stout, J.C., Bonner, J., Hesselink, J.R., 2001. Effects of age on tissues and regions of the cerebrum and cerebellum. *Neurobiol. Aging* 22, 581–594.
- Lindauer, R.J., Vlieger, E.J., Jalink, M., Olf, M., Carlier, I.V., Majoie, C.B., den Heeten, G.J., Gersons, B.P., 2004. Smaller hippocampal volume in Dutch police officers with posttraumatic stress disorder. *Biol. Psychiatry* 56, 356–363.
- Magnotta, V.A., Harris, G., Andreasen, N.C., O’Leary, D.S., Yuh, W.T., Heckel, D., 2002. Structural MR image processing using the BRAINS2 toolbox. *Comput. Med. Imaging Graph.* 26, 251–264.
- Neylan, T.C., Lenoci, M., Rothlind, J., Metzler, T.J., Schuff, N., Du, A.T., Franklin, K.W., Weiss, D.S., Weiner, M.W., Marmar, C.R., 2004. Attention, learning, and memory in posttraumatic stress disorder. *J. Trauma. Stress* 17, 41–46.

- Pantel, J., O'Leary, D.S., Cretsingher, K., Bockholt, H.J., Keefe, H., Magnotta, V.A., Andreasen, N.C., 2000. A new method for the in vivo volumetric measurement of the human hippocampus with high neuroanatomical accuracy. *Hippocampus* 10, 752–758.
- Pederson, C.L., Maurer, S.H., Kaminski, P.L., Zander, K.A., Peters, C.M., Stokes-Crowe, L.A., Osborn, R.E., 2004. Hippocampal volume and memory performance in a community-based sample of women with posttraumatic stress disorder secondary to child abuse. *J. Trauma. Stress* 17, 37–40.
- Sapolsky, R.M., 1996. Why stress is bad for your brain. *Science* 273, 749–750.
- Schnyder, U., Moergeli, H., 2002. German version of Clinician-Administered PTSD Scale. *J. Trauma. Stress* 15, 487–492.
- Schuff, N., Marmar, C.R., Weiss, D.S., Neylan, T.C., Schoenfeld, F., Fein, G., Weiner, M.W., 1997. Reduced hippocampal volume and *n*-acetyl aspartate in posttraumatic stress disorder. *Ann. N. Y. Acad. Sci.* 821, 516–520.
- Shin, L.M., Shin, P.S., Heckers, S., Krangel, T.S., Macklin, M.L., Orr, S.P., Lasko, N., Segal, E., Makris, N., Richert, K., Levering, J., Schacter, D.L., Alpert, N.M., Fischman, A.J., Pitman, R.K., Rauch, S.L., 2004. Hippocampal function in posttraumatic stress disorder. *Hippocampus* 14, 292–300.
- Stein, M.B., Koverola, C., Hanna, C., Torchia, M.G., McClarty, B., 1997. Hippocampal volume in women victimized by childhood sexual abuse. *Psychol. Med.* 27, 951–959.
- Villarreal, G., Hamilton, D.A., Petropoulos, H., Driscoll, I., Rowland, L.M., Griego, J.A., Kodituwakku, P.W., Hart, B.L., Escalona, R., Brooks, W.M., 2002. Reduced hippocampal volume and total white matter volume in posttraumatic stress disorder. *Biol. Psychiatry* 52, 119–125.
- Vythilingam, M., Heim, C., Newport, J., Miller, A.H., Anderson, E., Bronen, R., Brummer, M., Staib, L., Vermetten, E., Charney, D.S., Nemeroff, C.B., Bremner, J.D., 2002. Childhood trauma associated with smaller hippocampal volume in women with major depression. *Am. J. Psychiatry* 159, 2072–2080.
- Winter, H., Irlle, E., 2004. Hippocampal volume in adult burn patients with and without posttraumatic stress disorder. *Am. J. Psychiatry* 161, 2194–2200.
- Yehuda, R., Kahana, B., Binder-Brynes, K., Southwick, S.M., Mason, J.W., Giller, E.L., 1995. Low urinary cortisol excretion in Holocaust survivors with posttraumatic stress disorder. *Am. J. Psychiatry* 152, 982–986.