

Available online at [www.sciencedirect.com](http://www.sciencedirect.com)

ScienceDirect

Journal homepage: [www.elsevier.com/locate/cortex](http://www.elsevier.com/locate/cortex)

## Note

## From baby brain to mommy brain: Widespread gray matter gain after giving birth



Eileen Luders <sup>a,b,1</sup>, Florian Kurth <sup>a,1</sup>, Malin Gingnell <sup>c,d</sup>, Jonas Engman <sup>c</sup>,  
Eu-Leong Yong <sup>d</sup>, Inger S. Poromaa <sup>e,\*</sup> and Christian Gaser <sup>f</sup>

<sup>a</sup> School of Psychology, University of Auckland, Auckland, New Zealand

<sup>b</sup> Laboratory of Neuro Imaging, School of Medicine, University of Southern California, Los Angeles, USA

<sup>c</sup> Department of Psychology, Uppsala University, Uppsala, Sweden

<sup>d</sup> Department of Obstetrics and Gynecology, National University Hospital, National University of Singapore, Singapore

<sup>e</sup> Department of Women's and Children's Health, Uppsala University, Uppsala, Sweden

<sup>f</sup> Departments of Psychiatry and Neurology, Jena University Hospital, Jena, Germany

## ARTICLE INFO

## Article history:

Received 13 May 2019

Reviewed 02 July 2019

Revised 26 August 2019

Accepted 16 December 2019

Action editor Pia Rotshtein

Published online 28 January 2020

## Keywords:

Brain

Gray matter

Structural MRI

Peripartum

Postpartum

Pregnancy

VBM

## ABSTRACT

Pregnancy results in obvious physiological changes to the female body, but data as to what happens to the maternal brain after giving birth are sparse as well as inconsistent. The overall goal of this study is to determine the nature of cerebral change in the postpartum period. For this purpose, we analyzed T1-weighted brain images of 14 healthy women (age range: 25–38 years) at two time points, specifically within 1–2 days of childbirth (immediate postpartum) and at 4–6 weeks after childbirth (late postpartum). When comparing voxel-wise gray matter between these two time points, there was no evidence of any significant decrease. Instead, we detected a pronounced gray matter increase involving both cortical and subcortical regions, such as the pre- and postcentral gyrus, the frontal and central operculum, the inferior frontal gyrus, the precuneus, and the middle occipital gyrus, as well as the thalamus and caudate. These structural changes occurring within only 4–6 weeks after delivery are reflective of a high degree of neuroplasticity and massive adaptations in the maternal brain. They may suggest a restoration of brain tissue following pregnancy and/or a substantial brain reorganization, possibly to accommodate a multifaceted repertoire of complex behaviors associated with being a mother.

© 2020 Elsevier Ltd. All rights reserved.

\* Corresponding author.

E-mail address: [inger.sundstrom@kbh.uu.se](mailto:inger.sundstrom@kbh.uu.se) (I.S. Poromaa).

<sup>1</sup> Both authors contributed equally.

<https://doi.org/10.1016/j.cortex.2019.12.029>

0010-9452/© 2020 Elsevier Ltd. All rights reserved.

## 1. Introduction

During pregnancy, the maternal body undergoes enormous physiological adaptations, which may also manifest in the macrostructure of the brain. However, research in this field is extremely sparse (Barba-Muller et al., 2019). This could be due to strong regulations imposed on magnetic resonance imaging (MRI) during pregnancy, as well as the understandable reluctance of women who plan to become pregnant, are pregnant, or who have recently given birth to undergo voluntary MRI scanning. However, overall, there still seems to be general consensus among the few imaging studies that pregnancy is accompanied by decreases in brain size, tissue volumes, and various cortical measures, such as thickness, surface area, and gyrification (Carmona et al., 2019; Hoekzema et al., 2017; Oatridge et al., 2002).

In contrast, analyses focusing on what happens after pregnancy revealed inconsistent findings: While four studies revealed tissue increases or lower brain ages (Oatridge et al., 2002; Luders et al., 2018; Kim et al., 2010; Lisofsky et al., 2019), one study reported that volume reductions accompanying pregnancy endure for at least two years<sup>2</sup> (Hoekzema et al., 2017). However, as summarized in Table 1, studies are not easily comparable because of their diverse morphological measures, their different sample sizes, as well as their varying data collection points, the latter not only in terms of whether any pre-pregnancy or pregnancy data exist, but also when post-pregnancy data are acquired. For example, while some studies acquired data peripartum and at about 4–6 weeks postpartum (Luders et al., 2018; Oatridge et al., 2002), others collected data at 2–4 weeks and 3–4 months postpartum (Kim et al., 2010), about 2 months and 4–5 months postpartum (Lisofsky et al., 2019), or at 10 weeks and 2.3 years postpartum (Hoekzema et al., 2017). Importantly, as it takes several weeks after giving birth before the hormonal environment resembles the non-pregnant state (Bloch, Daly, & Rubinow, 2003), structural MRI data obtained within a few days of delivery serve as an approximation of the brain in late pregnancy (Luders et al., 2018). Thus, comparing data between immediate postpartum and at a later point in time after giving birth will provide valuable insights into how the maternal brain in the antenatal period (also often referred to as ‘baby brain’) might differ from the ‘mommy brain’.

Previous research from our team revealed lower brain ages at 4–6 weeks postpartum compared to 1–2 days postpartum, suggesting a possible rejuvenation effect in the maternal brain (Luders et al., 2018). Given that declining cerebral tissue is a trademark of brain aging, we had hypothesized that seemingly younger brains are a consequence of gray matter increase after giving birth. However, our previous study (Luders et al., 2018) did not measure gray matter directly and also provided no definitive answer in terms of the brain regions affected. To our knowledge, there are only two studies that focused on gray matter changes and that reported wide-spread tissue increases after pregnancy (Kim et al., 2010; Lisofsky et al., 2019). More specifically, the first study detected significant

effects within the superior, middle and inferior prefrontal cortex, the pre- and postcentral gyrus, the superior and inferior parietal lobe, as well as within the insula and the thalamus (Kim et al., 2010). The second study observed significant effects within the cingulate/ventromedial prefrontal cortex, the middle frontal gyrus, the cerebellum, and the nucleus accumbens (Lisofsky et al., 2019). However, those effects were evident when comparing data acquired at 3–4 months and at 2–4 weeks postpartum (Kim et al., 2010) or even at 4–5 months compared to about 2 months postpartum (Lisofsky et al., 2019), times at which many pregnancy-related physiological adaptations have already normalized.

We hypothesized that by shifting the time frame closer to birth, we would observe even more pronounced changes, presumably tissue increases, in the maternal brain. The aim of our study was thus to determine the direction and location of longitudinal gray matter alterations when comparing brain image data acquired within 1–2 days of giving birth (immediate postpartum) and after 4–6 weeks of giving birth (late postpartum).

## 2. Methods

### 2.1. Study participants

The study was based on 14 healthy postpartum women between 25 and 38 years of age (mean  $\pm$  SD: 32.8  $\pm$  4.0 years). Importantly, all women underwent normal pregnancies and uncomplicated deliveries ( $n = 9$  vaginal;  $n = 5$  Caesarean). For half of the women ( $n = 7$ ), this was a first-time delivery. All women ( $n = 14$ ) were breastfeeding at the time of the late postpartum brain scan. A detailed description of the study sample, including exclusion criteria, is provided elsewhere (Luders et al., 2018). None of the study procedures or analyses were pre-registered prior to the research being conducted. All procedures were approved by the Regional Ethical Review Board, Uppsala (Sweden), and all participants provided written informed consent. The conditions of our ethics approval do not permit public archiving of anonymised study data. Readers seeking access to the data should contact the corresponding author. Access will be granted to named individuals after completion of a formal data sharing agreement, in accordance with ethical procedures governing the reuse of sensitive data.

### 2.2. Brain data acquisition and preprocessing

All brain images were acquired using a Philips Achieva 3T-X MRI system (R2.1.3) applying a phase-sensitive inversion recovery (PSIR) T1-weighted sequence and the following parameters: 5,700 ms repetition time, 15 ms echo time, 400 ms inversion time, 90° flip angle, 23 cm field of view, and .45  $\times$  .45  $\times$  2.0 mm<sup>3</sup> voxel size. For each participant, brain images were acquired at two different time points, more specifically at 27  $\pm$  10 h (i.e., 1–2 days; immediate postpartum) after delivery and at 34  $\pm$  5 days (i.e., 4–6 weeks; late postpartum) after delivery.

All brain images were processed in Matlab (<http://www.mathworks.com/products/matlab>) using SPM8 (<http://www.fil.ion.ucl.ac.uk/spm>) and the VBM8 toolbox ([<sup>2</sup> With the exception of a partial recovery of the hippocampal volume.](http://dbm.</a></p>
</div>
<div data-bbox=)

**Table 1 – Overview and outcomes of existing studies.**

Study	Primary Measure	MRI Before Pregnancy	MRI During Pregnancy	MRI After Pregnancy				Study Outcomes
				day(s)	weeks	months	year(s)	
<a href="#">Oatridge et al. (2002)</a>	brain size, ventricle size	n = 2	at week 15–30 (n = 2); at week 37–42 (n = 15)	–	at week 6 (n = 14)	at week 24 (n = 10); at week 40 (n = 5)	at week 52 (n = 6)	- decreases in brain size during pregnancy (smallest at term) that reversed by 6 months after delivery - increases in ventricle size during pregnancy and decrease after delivery
<a href="#">Kim et al. (2010)</a>	voxel-wise gray matter	–	–	–	at week 2–4 (n = 19)	at month 3–4 (n = 19)	–	- increases in gray matter in several brain regions at 3–4 months compared to 2–4 weeks after delivery
<a href="#">Hoekzema et al. (2017)</a>	voxel-wise gray matter	n = 25	–	–	–	at week 10 (n = 25)	at year 2.3 (n = 11)	- decreases in gray matter in several brain regions at 10 weeks (mean ± SD: 73.56 ± 47.83 days) and at 2.3 years (mean ± SD: 2.3 ± .50 years) after delivery compared to before pregnancy - no decreases or increases between 10 weeks and 2.3 years, with the exception of the hippocampus showing an increase
<a href="#">Luders et al. (2018)</a>	brain age	–	–	at day 1–2 (n = 14)	at week 4–6 (n = 14)	–	–	- lower brain ages at 4–6 weeks (mean ± SD: 34 ± 5 days) compared to 1–2 days (mean ± SD: 27 ± 10 h) after delivery
<a href="#">Lisofsky et al. (2019)</a>	voxel-wise gray matter	–	–	–	within 2 months of delivery (n = 24)	at 4–5 months after delivery (n = 24)	–	- increases in gray matter in several brain regions at 4–5 months after delivery compared to within 2 months of delivery

n refers to the number of pre-pregnant, pregnant, and post-pregnant women scanned at each time point.

neuro.uni-jena.de/vbm). In particular, we applied a voxel-based morphometry (VBM) workflow optimized for longitudinal processing, as further described elsewhere (Kurth et al., 2014a; Kurth et al., 2014b; see also <http://dbm.neuro.uni-jena.de/vbm8/VBM8-Manual.pdf>). Briefly, for each subject, the images from immediate postpartum and late postpartum were first bias-field corrected and halfway-registered using rigid-body transformations. In addition, a subject-specific mean image was calculated from time points 1 and 2. Subsequently, all registered images from time point 1, from time point 2, as well as the mean image were tissue-classified into gray matter, white matter, and cerebrospinal fluid, while accounting for partial volume effects (Tohka, Zijdenbos, & Evans, 2004). Following this step, the resulting gray matter segments of the mean images were normalized to the DARTEL-Template (as supplied with the VBM8 Toolbox), using linear (affine) and non-linear (warping) registrations (Ashburner, 2007). The spatial transformations derived from this normalization procedure were then applied to the gray matter segments at the two time points. Subsequently, the normalized gray matter segments were multiplied by the Jacobian determinant derived from the normalization matrix (modulation). Finally, the resulting modulated gray matter segments at time point 1 were subtracted from the spatially normalized gray matter segments at time point 2 yielding one difference image per subject, which was then smoothed with an  $8 \times 8 \times 8 \text{ mm}^3$  (FWHM) Gaussian kernel.

### 2.3. Statistical analysis

The smoothed difference images were analyzed using a one-sample t-test to uncover any significant changes in voxel-wise gray matter between immediate postpartum and late postpartum. To control for false positives – given that statistical analyses were conducted at thousands of data points – we used threshold-free cluster enhancement (TFCE; Smith & Nichols, 2009) in conjunction with a family-wise error (FWE) correction and an alpha of .01. Additional maps were generated at an even stricter threshold of .001 to facilitate and guide the region-specific interpretation of findings. Importantly, TFCE relies on permutation and as such constitutes a non-parametric approach. Thus, it does not require data to be normally distributed. TFCE has the additional benefit of integrating cluster information (number of voxels) with voxel-wise statistical inference (peak voxel significance) and as such enhances the detectability of effects overall (Smith & Nichols, 2009).

### 2.4. Supplemental analysis

In addition to the main analysis testing for voxel-wise gray matter changes between immediate postpartum and late postpartum, we also tested whether total intracranial volume (TIV) – derived as the sum of total gray matter, total white matter, and total cerebrospinal fluid – changed over time. For this purpose, we subtracted the TIV at immediate postpartum from the TIV at late postpartum. However, the change of TIV over time (a minimal decrease) was negligible (mean [SD]:  $-2.35$  [11.89] ml) and not significant ( $p = .472$ ). This analysis served to ensure that any possible gray matter changes on the

local scale are not simply driven by major TIV changes on the global scale (which could have other, non-biological reasons).

## 3. Results

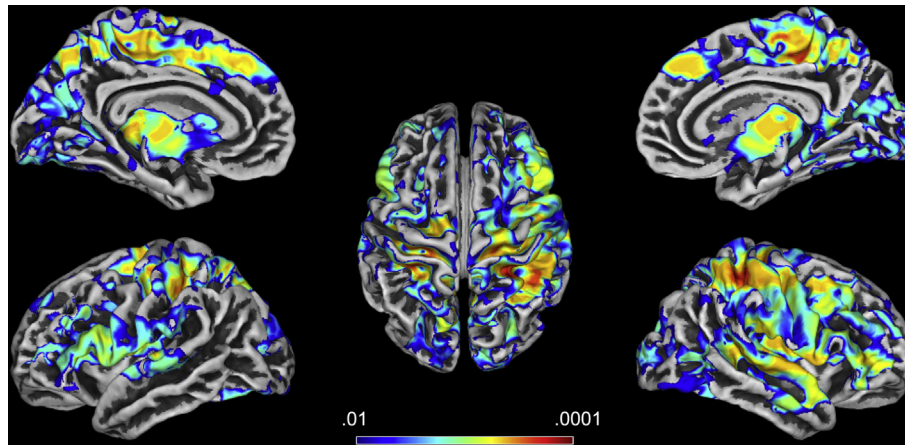
When testing for a significant change of voxel-wise gray matter between immediate postpartum (within 1–2 days of delivery) and late postpartum (at 4–6 weeks after delivery), there was no region with significant gray matter decrease. In contrast, there were many regions with significant gray matter increase. As illustrated in Fig. 1, when using a relatively strict threshold of  $p \leq .01$  (FWE-corrected), significant effects were wide-spread, evident in both hemispheres and all four lobes, and involved both cortical and subcortical regions. Effect sizes for the significance clusters are very high with Cohen's  $d$  values between 1.6 and 6.4, as further illustrated in Supplemental Figure 1. Of note, 95% of all values were in the range of  $d = 1.61$ –2.98.

When using an even stricter threshold of  $p \leq .001$  (FWE-corrected), there were still numerous regions – altogether comprising of seven clusters (C1–C7) – where gray matter increased significantly between immediate postpartum and late postpartum (see Table 2). More specifically, the largest cluster (C1) contains 32,220 voxels traveling from the left central sulcus over to the right hemisphere, where it covers large parts of the pre- and postcentral gyrus. Within the right hemisphere, the cluster extends further anteriorly towards the middle and inferior frontal gyrus, as well as posteriorly over the superior parietal lobe and the intraparietal sulcus towards the inferior parietal lobe, the insula and the temporal lobe. The significance maximum of C1 is located within the right postcentral gyrus at  $x = 33$ ;  $y = -36$ ;  $z = 57$  (MNI space). The second largest cluster (C2) contains 3,384 voxels, covers the left and right thalamus, and extends anteriorly into the hypothalamus. The significance maximum of C2 is located within the left thalamus at  $x = -20$ ;  $y = -26$ ;  $z = 0$  (MNI space). The third largest cluster (C3) contains 1,719 voxels and covers the left perisylvian region, extending from the inferior frontal gyrus in Broca's region posteriorly over the frontal and parietal operculum, including the secondary somatosensory cortex, to the posterior insula. The significance maximum of C3 is located within the left central operculum at  $x = -52$ ;  $y = -12$ ;  $z = 9$  (MNI space). For details on the other four smaller clusters, please see Table 2. For section views of the significant gray matter increase between immediate postpartum and late postpartum at  $p \leq .001$ , please see Supplemental Figure 2.

## 4. Discussion

Given the sparseness of studies investigating postpartum changes in the maternal brain, we applied VBM to determine the presence, direction, and extent of gray matter change after giving birth. VBM constitutes an ideal choice of method for this question because it allows for the voxel-wise examination of effects across the entire brain without requiring the *a priori* definition of particular regions of interest. Moreover, VBM does not only provide a high regional specificity (changes are detectable on the voxel level) but also the required temporal





**Fig. 1 – Change in voxel-wise gray matter between immediate postpartum (within 1–2 days of delivery) and late postpartum (at 4–6 weeks after delivery) at  $p \leq .01$ . The results are projected onto surface models of the standard template (as supplied with the CAT Toolbox: <http://dbm.neuro.uni-jena.de/cat/>) in MNI space. The color bar encodes significance (FWE-corrected). All colored clusters indicate significant gray matter increases between the two time points. There was no significant gray matter decrease.**

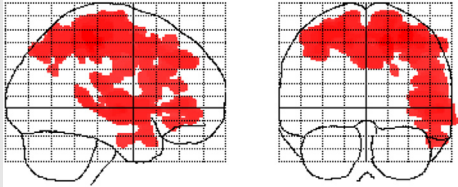
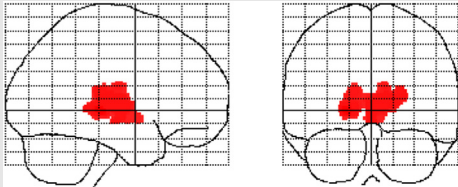
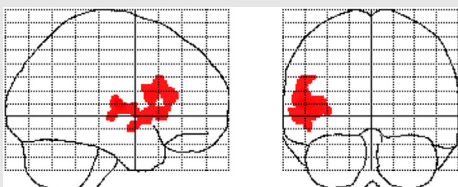
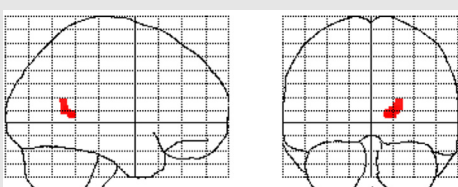
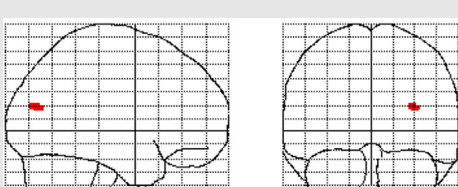
sensitivity (changes are detectable within weeks), as demonstrated in numerous studies on brain plasticity (Boyke et al., 2008; Draganski et al., 2004, 2006), including those capturing changes over the menstrual cycle (De Bondt et al., 2016; Lisofsky et al., 2015; Pletzer et al., 2010, 2018; Protopopescu et al., 2008). When comparing voxel-wise gray matter between immediate postpartum and late postpartum, there was no evidence of any significant decrease whatsoever. In contrast, significant gray matter increase was wide-spread across the brain, not only involving cortical regions but also subcortical structures. That is, if the maternal body undergoes enormous changes during pregnancy overall (Brunton & Russell, 2008), then these current findings imply a similarly massive (re)adjustment *after* giving birth in terms of the macro-structure of the human brain.

#### 4.1. Correspondence with previous findings

At this point, there seem to be only five other studies in humans that addressed changes in the brain's macro-structure during the postpartum period (see Table 1). In terms of the direction of the effect, our study is in agreement with three studies (Kim et al., 2010; Lisofsky et al., 2019; Oatridge et al., 2002) that reported brain and gray matter increases (ventricle decreases, respectively) and in partial agreement with a fourth study (Hoekzema et al., 2017), which reported gray matter increases in the hippocampus (while other brain regions showed neither decrease nor increase). It also corroborates the outcomes of a fifth study, which revealed lower brain ages after giving birth (Luders et al., 2018) and led us to hypothesize that decreasing brain ages are driven by increasing gray matter. In terms of the time frame assessed, our study is closest to Oatridge's study (Oatridge et al., 2002), where the main bulk of data was obtained around term and at six weeks postpartum. Oatridge and colleagues reported a significant increase in brain

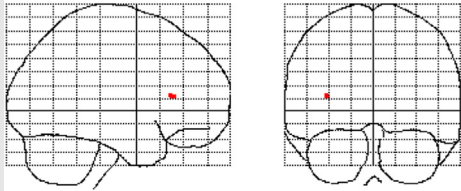
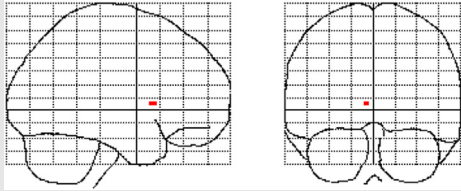
volume, which resembles our observed increase in gray matter. In terms of the morphometric measure, our study is comparable to Kim's, Hoekzema's and Lisofsky's studies that also examined voxel-wise gray matter (Hoekzema et al., 2017; Kim et al., 2010; Lisofsky et al., 2019). Lisofsky and colleagues (2019) included a control group and analyzed time-by-group interactions with significant effects occurring within prefrontal, frontal, and cerebellar regions as well as the nucleus accumbens. The accompanying interaction plots clearly suggest gray matter increases within postpartum mothers only. However,  $p$ -values have only been provided for the mean gray matter volume increase across all significance clusters (and only for a sub-group analysis), rather than separately for each significance cluster. Thus, we will abstain from over-interpreting the cluster location and spatial extent in relation to our current findings. Importantly, postpartum decreases in Lisofsky's study were not evident whatsoever, which is in strong agreement with our study. Similarly, Hoekzema et al. (2017) did not detect any (further) postpartum decreases between week 10 and 2.3 years, but also no increases either, except for the hippocampus. At first sight, this may seem at odds with the many regions in the current study, where significant gray matter increases were detected. However, importantly, Hoekzema's analysis comparing two time points postpartum was restricted to areas that had shown significant decreases in their preceding analyses comparing postpartum to pre-pregnancy. That is, effects in any other brain region would not have been captured. Moreover, out of the 25 women who underwent brain imaging before pregnancy and at the initial time point postpartum, only 11 women were able to receive a brain scan at the follow-up time point postpartum, which might have additionally impacted the outcomes. Last but not least, the initial and follow-up postpartum data were acquired at around 10 weeks and at 2.3 years on average (compared to 1–2 days and 4–6 weeks in the current study) from 100%

**Table 2 – Cluster-specific details for significant gray matter increases from immediate postpartum to late postpartum at  $p \leq .001$ .**

General Information on Clusters 1-7		Information on Local Maxima within each Cluster			
Location (in red)		Size (in ml)	x-, y-, z-coordinates (MNI space)	Anatomical Region (atlas-based) <sup>a</sup>	p-value (FWE-corrected)
C1		108.74	33 -36 57	R postcentral gyrus	<.001
			16 -33 54	R medial precentral gyrus	<.001
			20 -33 46	R medial precentral gyrus	<.001
C2		11.42	-20 -26 0	L thalamus	<.001
			14 -20 8	R thalamus	<.001
			6 -12 6	R thalamus	<.001
C3		5.80	-52 -12 9	L central operculum	<.001
			-45 18 2	L frontal operculum	.001
			-51 12 15	L inferior frontal gyrus	.001
C4		.40	14 -50 6	R precuneus	<.001
C5		.10	33 -75 18	R middle occipital gyrus	.001

(continued on next page)

Table 2 – (continued)

	General Information on Clusters 1-7		Information on Local Maxima within each Cluster		
	Location (in red)	Size (in ml)	x-, y-, z-coordinates (MNI space)	Anatomical Region (atlas-based) <sup>a</sup>	p-value (FWE-corrected)
C6		.01	–36 26 12	L frontal operculum	.001
C7		.02	–6 12 4	L caudate	.001

L = Left, R = Right, MNI = Montreal Neurological Institute, FWE=Family-wise Error.  
<sup>a</sup> Neuromorphometrics atlas (<http://www.neuromorphometrics.com>).

primiparous mothers (compared to 50% primiparous mothers in the current study).

Considering all the different sources of discrepancies, our study seems most relatable to Kim's study (2010), with 42.1% multiparous mothers, which also utilized a whole-brain voxel-based approach without regional restrictions and which acquired data at 2–4 weeks and at 3–4 months. Kim and colleagues reported gray matter increases within the superior, middle, and inferior prefrontal cortex, the pre- and postcentral gyrus, the superior and inferior parietal lobe, as well as the insula and thalamus (Kim et al., 2010). Corroborating those findings, we observed significant gray matter increases within the superior, middle, and inferior prefrontal cortex, the pre- and postcentral gyrus, superior and inferior parietal lobe, as well as the insula and thalamus.<sup>3</sup> Interestingly, we observed additional gray matter increases within the precuneus, the middle occipital gyrus, and the caudate. The additional increases observed in the current study suggest that dramatic changes in maternal gray matter may occur within the first few weeks – possibly days – after giving birth, with the degree of change subsequently diminishing over the next months.

#### 4.2. Regional specificity and possible mechanisms

The observed increase in gray matter was not evident uniformly across the entire brain, but confined to particular

regions. Some of these regions (i.e., thalamus, caudate, and precentral gyrus) were also identified using functional imaging of maternal responses to her offsprings (Paul et al., 2019). Moreover, as discussed elsewhere (Kim et al., 2010), additional insights come from research on mammalian models: In lactating rats, for example, it was observed that physical interactions with pups and suckling stimuli during nursing are associated with the reorganization of the thalamus, parietal lobe, and somatosensory cortex. Conversely, lesions in the medial prefrontal cortex have been shown to lead to severe deficits in maternal behaviors, such as absence of pup retrieval and licking. Thus, the current findings of increased regional gray matter (see Fig. 1 and Table 2) may reflect a neural reorganization serving the need to accommodate a multi-faceted repertoire of complex behaviors associated with being a mother (Abraham et al., 2014; Anderson & Rutherford, 2012). In agreement with this assumption, engaging in intense mental activities and/or stimulating environments has been suggested to fuel dendritic branching and synaptogenesis (Birch, McGarry, & Kelly, 2013; Greenwood & Parasuraman, 2010). In other words, changes on the micro-anatomical level might manifest as changes on the macro-anatomical level, such as those observed here as increased gray matter. Alternatively, gray matter increases at late postpartum compared to immediate postpartum might simply reflect a restoration of the tissue that was lost during pregnancy, as discussed at length elsewhere (Lisofsky et al., 2019; Oatridge et al., 2002). It is also possible that any gray matter increases (or at least increases in particular regions) are a result of both, brain reorganization and tissue restoration. Our aforementioned study

<sup>3</sup> Please note that Table 2 only lists the names of the anatomical regions for the local maxima (and only at the stricter threshold of  $p < .001$ ). Each significance cluster contains additional regions (e.g., the insula in C1) not listed in the table.

revealing a lower brain age at late postpartum compared to immediate postpartum (Luders et al., 2018) suggested a rejuvenation effect in the maternal brain after giving birth. On the one hand, this might be in accordance with the concept of tissue restoration after giving birth, but on the other hand it could also be reflective of brain reorganization – as both postulates exist on the premise that there is an inverse link between brain aging and tissue increase. Regardless of the driving force, the pronounced structural changes within a relatively short time period of 4–6 weeks add further evidence to the notion that the human brain is highly plastic, even in adulthood.

## 5. Summary and future research

The current outcomes extend existing work in this understudied field of research by revealing the direction and location of tissue increase after pregnancy. The presence of tissue increase (rather than decrease) may reflect restoration and/or reorganization in the female brain after giving birth. Further research is clearly warranted, ideally by extending the sample size, by including functional, behavioral and/or observational measures, by testing for possible effects of breastfeeding, sleep deprivation, parity, and prior pregnancies and by adding a control group. Moreover, including further data collection points, before pregnancy and/or after delivery would provide novel insights: For example obtaining additional pre-pregnancy brain data, would allow mapping the exact location of individual change from before pregnancy to short after pregnancy (days) to long after pregnancy (weeks or months) to better disentangle the aforementioned effects due to restoration and reorganization. Moreover, postpartum data collection points even further in the future (years) would provide crucial insights into when the gray matter stops to increase and perhaps even starts to decrease again. Varying effects across different brain regions are likely, and expanding the spectrum of brain measures (cortical thickness, cortical complexity, fiber integrity, etc.) might expose further differential effects.

## CRedit authorship contribution statement

**Eileen Luders:** Conceptualization, Writing - original draft, Writing - review & editing, Visualization. **Florian Kurth:** Methodology, Writing - review & editing, Visualization. **Malin Gingnell:** Project administration, Investigation, Writing - review & editing. **Jonas Engman:** Investigation, Writing - review & editing. **Eu-Leong Yong:** Writing - review & editing. **Inger S. Poromaa:** Project administration, Investigation, Resources, Writing - review & editing, Supervision, Funding acquisition. **Christian Gaser:** Methodology, Formal analysis, Visualization.

## Acknowledgments

This study was supported by a research grant from the Swedish Research Council to I.S.P. (K2014-54X-20642-07-4).

## Supplementary data

Supplementary data to this article can be found online at <https://doi.org/10.1016/j.cortex.2019.12.029>.

## REFERENCES

- Abraham, E., Hendler, T., Shapira-Lichter, I., et al. (2014). Father's brain is sensitive to childcare experiences. *Proceedings of the National Academy of Sciences of the United States of America*, 111, 9792–9797.
- Anderson, M. V., & Rutherford, M. D. (2012). Cognitive reorganization during pregnancy and the postpartum period: An evolutionary perspective. *Evolutionary psychology: an international journal of evolutionary approaches to psychology and behavior*, 10, 659–687.
- Ashburner, J. (2007). A fast diffeomorphic image registration algorithm. *Neuroimage*, 38, 95–113.
- Barba-Muller, E., Craddock, S., Carmona, S., et al. (2019). Brain plasticity in pregnancy and the postpartum period: Links to maternal caregiving and mental health. *Archives of women's mental health*, 22, 289–299.
- Birch, A. M., McGarry, N. B., & Kelly, A. M. (2013). Short-term environmental enrichment, in the absence of exercise, improves memory, and increases NGF concentration, early neuronal survival, and synaptogenesis in the dentate gyrus in a time-dependent manner. *Hippocampus*, 23, 437–450.
- Bloch, M., Daly, R. C., & Rubinow, D. R. (2003). Endocrine factors in the etiology of postpartum depression. *Comprehensive psychiatry*, 44, 234–246.
- Boyke, J., Driemeyer, J., Gaser, C., et al. (2008). Training-induced brain structure changes in the elderly. *The Journal of Neuroscience: the Official Journal of the Society for Neuroscience*, 28, 7031–7035.
- Brunton, P. J., & Russell, J. A. (2008). The expectant brain: Adapting for motherhood. *Nature reviews. Neuroscience*, 9, 11–25.
- Carmona, S., Martinez-Garcia, M., Paternina-Die, M., et al. (2019). Pregnancy and adolescence entail similar neuroanatomical adaptations: A comparative analysis of cerebral morphometric changes. *Human brain mapping*, 40, 2143–2152.
- De Bondt, T., Pullens, P., Van Hecke, W., et al. (2016). Reproducibility of hormone-driven regional grey matter volume changes in women using SPM8 and SPM12. *Brain structure & function*, 221, 4631–4641.
- Draganski, B., Gaser, C., Busch, V., et al. (2004). Neuroplasticity: Changes in grey matter induced by training. *Nature*, 427, 311–312.
- Draganski, B., Gaser, C., Kempermann, G., et al. (2006). Temporal and spatial dynamics of brain structure changes during extensive learning. *The Journal of Neuroscience: the Official Journal of the Society for Neuroscience*, 26, 6314–6317.
- Greenwood, P. M., & Parasuraman, R. (2010). Neuronal and cognitive plasticity: A neurocognitive framework for ameliorating cognitive aging. *Frontiers in aging neuroscience*, 2, 150.
- Hoekzema, E., Barba-Muller, E., Pozzobon, C., et al. (2017). Pregnancy leads to long-lasting changes in human brain structure. *Nature neuroscience*, 20, 287–296.
- Kim, P., Leckman, J. F., Mayes, L. C., et al. (2010). The plasticity of human maternal brain: Longitudinal changes in brain anatomy during the early postpartum period. *Behavioral neuroscience*, 124, 695–700.
- Kurth, F., Luders, E., Sicotte, N. L., et al. (2014a). Neuroprotective effects of testosterone treatment in men with multiple sclerosis. *Neuroimage Clin*, 4, 454–460.



- Kurth, F., Luders, E., Wu, B., et al. (2014b). Brain gray matter changes associated with mindfulness meditation in older adults: An exploratory pilot study using voxel-based morphometry. *Neuro*, 1, 23–26.
- Lisofsky, N., Gallinat, J., Lindenberg, U., et al. (2019). Postpartal neural plasticity of the maternal brain: Early renormalization of pregnancy-related decreases? *Neurosignals*, 27, 12–24.
- Lisofsky, N., Martensson, J., Eckert, A., et al. (2015). Hippocampal volume and functional connectivity changes during the female menstrual cycle. *NeuroImage*, 118, 154–162.
- Luders, E., Gingnell, M., Poromaa, I. S., et al. (2018). Potential brain age reversal after pregnancy: Younger brains at 4–6 weeks postpartum. *Neuroscience*, 386, 309–314.
- Oatridge, A., Holdcroft, A., Saeed, N., et al. (2002). Change in brain size during and after pregnancy: Study in healthy women and women with preeclampsia. *AJNR. American journal of neuroradiology*, 23, 19–26.
- Paul, S., Austin, J., Elliott, R., et al. (2019). Neural pathways of maternal responding: Systematic review and meta-analysis. *Archives of women's mental health*, 22, 179–187.
- Pletzer, B., Harris, T., & Hidalgo-Lopez, E. (2018). Subcortical structural changes along the menstrual cycle: Beyond the hippocampus. *Scientific reports*, 8, 16042.
- Pletzer, B., Kronbichler, M., Aichhorn, M., et al. (2010). Menstrual cycle and hormonal contraceptive use modulate human brain structure. *Brain research*, 1348, 55–62.
- Protopopescu, X., Butler, T., Pan, H., et al. (2008). Hippocampal structural changes across the menstrual cycle. *Hippocampus*, 18, 985–988.
- Smith, S. M., & Nichols, T. E. (2009). Threshold-free cluster enhancement: Addressing problems of smoothing, threshold dependence and localisation in cluster inference. *Neuroimage*, 44, 83–98.
- Tohka, J., Zijdenbos, A., & Evans, A. (2004). Fast and robust parameter estimation for statistical partial volume models in brain MRI. *Neuroimage*, 23, 84–97.